

AOMSI Radiology Report Layout – Linear Translation

Create a Report - Polly PI

Must select at least one

- Angulation Analysis (Flexion - 5th or 6th Editions)
- Relative Translation (Flexion/Extension - 5th or 6th Editions)
- Linear Translation (Flexion/Extension - 5th Edition only)

Optional

- Measurement Graphs
- Posterior Vertebral Body Line Analysis - George's Line (Neutral)
- ALL and PLL Diagrams and Explanations
- Total Linear and Relative Translation (Flexion/Extension)
- Relative Translation (Neutral)
- Linear Translation (Neutral)
- Images with Dot Placement

< Back Exit Next >

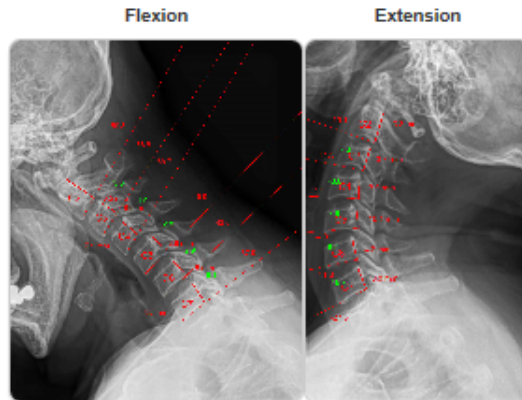
The flexion and extension views with the drawn Advanced Line Analysis will appear on the report with the Linear Translation Measurements containing the outcomes from the drawn analyses.

The Linear Translation Calculation Method will always appear as Figure C on the report, even if you don't select the prior Figures (Angulation Analysis or Relative Translation).

Cervical Spine Linear Translation (Flexion / Extension)

Clinical Relevance of Measurements & Analysis

Radiographic Linear Translation measurements can be used in diagnosing Alteration Of Motion Segment Integrity (AOMSI). Radiographic Linear Translation is an alternate method of calculating Translation to determine if AOMSI is present as described in the Fifth Edition (Errata) of the AMA Guides.^{1,3,5-6} An AOMSI diagnosis, indicating significant permanent ligament injury and alteration of motion of the cervical spine, qualifies the patient for a permanent impairment rating if the linear translation exceeds 3.5 mm at a motion segment with confirmation of clinical correlation and MMI established. The measurements in this section were obtained from the patient's cervical flexion and extension radiographic views in accordance with the linear translation methodologies described in the AMA Guides.^{3,5-8}

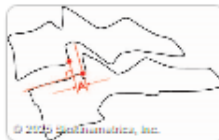

Linear Translation Measurements

Motion Segment	Flexion Translation (A) (mm)	Extension Translation (A) (mm)
C2-C3	0.5 posterior	3.8 posterior
C3-C4	4.9 posterior	3.7 posterior
C4-C5	7.9 anterior	3.9 posterior
C5-C6	3.8 posterior	10.1 posterior
C6-C7	1.5 posterior	4.2 posterior

The Linear Translation measurements for this patient's flexion and extension views are displayed in the above table for the cervical spine motion segments. If a linear threshold measurement of > 3.5mm is present, then a diagnosis of AOMSI is present. If AOMSI is present, it is bolded in the table above at the involved motion segment. A diagnosis of AOMSI qualifies the patient for a permanent impairment rating, with confirmation of clinical correlation and MMI, according to the 5th Edition of the AMA Guides, DRE Cervical Category IV, Section 15.6^{2,3} AOMSI presence provides evidence of ligament damage from injury and permanent alteration of motion at the respective motion segment. The Impressions and discussion on page 1 of this radiology AOMSI report describe the significance of the measurements and calculations. Additionally, the medical literature²⁻¹⁴ has published that linear translation measurements that are greater than 1.1 mm but below the AOMSI threshold of 3.5mm, demonstrates evidence of ligament damage from injury and alteration of motion at the motion segment, but not severe enough to be ratable by the AMA Guides.

Figure C: Linear Translation Calculation Method



The method for measuring linear translation is to measure distance A as shown in Figure C, which is the same as the Relative Translation measurement for determining the distance A. On the patient's radiographs of the cervical spine motion segments, a dot is placed at the posterior superior corner of the lower vertebra, and a separate dot is placed at the posterior inferior corner of the upper vertebra. The distance (A) is measured as illustrated by Figure C, using two parallel lines. Measurements are obtained in flexion and separately in extension.^{2,5-8} The patient's motion segment measurements are displayed in the Linear Translation Measurements table.