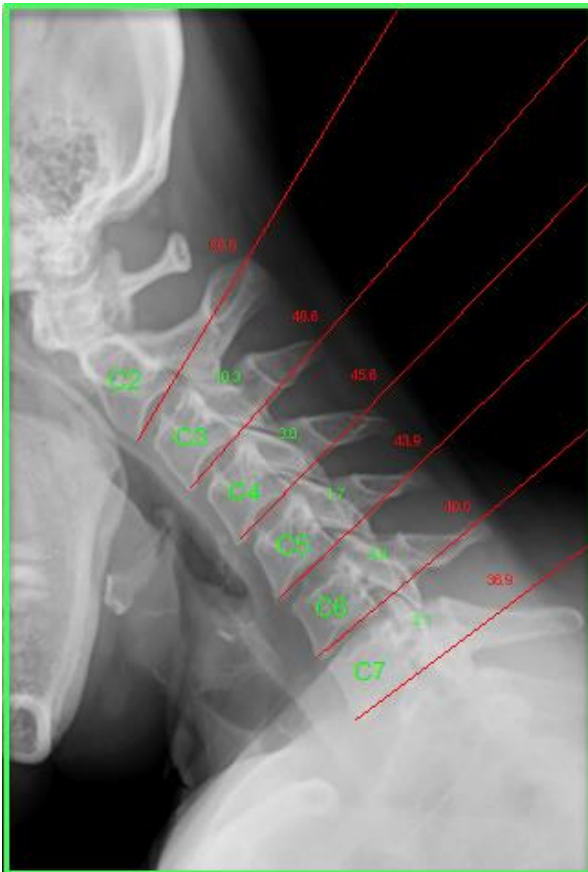


Vertebral Angulations



The Angulation Analysis is for the Flexion view only. On the image the angle measure will be in red. The measure in green is the angulation ° for the two vertebrae it is listed between. (i.e. C2-C3 angulation is listed between C2 and C3.)

An example of the Findings:

Discussion of Findings:

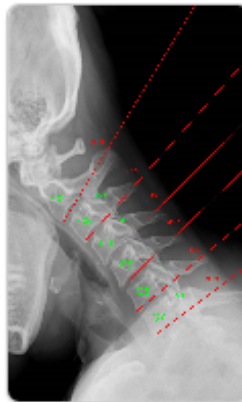
The patient's angulation measurements on the Flexion view do not exceed the threshold measurements for a ratable finding for AOMSI based on the *AMA Guides*¹⁻⁶. The motion segment C2-C3 is indicative of irregular motion and demonstrates evidence of ligament injury for angulation on the Flexion view with a measurement of 7.3 degrees.⁷⁻¹⁰

Cervical Spine Angulation Analysis

Clinical Relevance of Measurements & Analysis

Radiographic Angulation measurements can be used in diagnosing Alteration Of Motion Segment Integrity (AOMSI). Angulation measurements were obtained on the patient's cervical spine flexion view to determine if AOMSI is present as described in the AMA Guides.¹⁻⁸ An AOMSI diagnosis, indicating permanent ligament injury and alteration of motion of the cervical spine, qualifies the patient for a permanent impairment rating if the angulation measurement for the greatest difference between the vertebra above and below the respective motion segment exceeds 11 degrees. Confirmation of clinical correlation and MMI are required. If the Angulation method does not demonstrate AOMSI per the AMA Guides,³⁻⁴ other scientific literature⁹⁻¹² has been published demonstrating that measurements between 7 degrees and 11 degrees, also demonstrate significant ligament damage from injury and alteration of motion at the respective motion segment, but are not severe enough to be ratable. The methodologies for Angulation calculation and the patient's actual measurements are listed below.

Flexion View

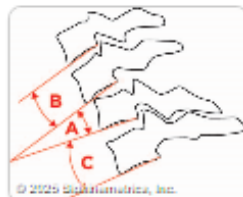


Angulation Measurements

Motion Segment	Angultion (°)	Greatest Difference
C2-C3	10.3	7.3
C3-C4	3.0	1.3
C4-C5	1.7	-1.3
C5-C6	3.9	2.2
C6-C7	3.1	-0.8

A diagnosis of AOMSI in the cervical spine by angular motion for alteration of motion segment integrity measurements requires an Angulation Greatest Difference measurement greater than 11 degrees at a motion segment to qualify the patient for a permanent impairment rating, if the patient has reached MMI and clinical correlation is confirmed.²⁴ Then, AOMSI ligament damage and alteration of motion is considered permanent if this threshold is met (AMA Guides)¹⁻⁸. The calculation method for measuring Angulation is described in Figure A below. Additionally, when angular motion is measured between 7 degrees and 11 degrees, it is considered a substantial variation from normal, indicating evidence for cervical spine ligament injury and laxity damage, as documented in the published literature,⁹⁻¹² but considered not to be severe enough for a ratable impairment.

Figure A - Angulation Measurement Calculation Method



The process to determine alteration of motion segment integrity by angular motion measurements is demonstrated in Figure A. The calculation method for angular motion in the cervical spine is defined as a difference greater than 11° angular motion at adjacent levels on the flexion radiograph, which is supported by the literature.¹⁻⁸ Lines are drawn along the inferior borders of the two vertebral bodies adjacent to the level in question and of the vertebral bodies above and below those two vertebrae. Angles A, B, and C are measured. Angulation loss of motion for determining alteration of motion segment integrity is defined as motion at the level in question that is more than 11° greater than at either adjacent level. The angle greatest difference between adjacent motion segments greater than 11° is used as criterion for determination of AOMSI angular alteration of motion. These parameters apply to the motion segments from C3 to C7 on the flexion view only.²⁻⁸